

Study on Structural and Histological Indices of the Umbilicus in Neonatal Asphyxia

Ju Hyon-Saeng

ABSTRACT

Background and Aim: Umbilical cord is a pathway of oxygen and nutrient supplies between mother and fetus, whose normal growth is essential for normal fetal growth. Even though it is grown enough, anomaly of umbilical cord can have negative affection on the fetus and neonate. The study was conducted to explain several structural and histological features of the umbilical cord that affect asphyxia neonatorum. **Methods:** Specimens were obtained from 85 cases of umbilical cords diagnosed as asphyxia neonatorum. We have evaluated the amount of Wharton's jelly, mast cell counts distributed around the umbilical vessels, muscular remnant and segmental thinning of umbilical vessels and the presence of thrombus. **Results:** At grade 2 asphyxia neonatorum, Wharton's jelly which composes umbilical cord and mast cell counts distributed around the vessels were significantly lower than the control group. There was no significant difference in the presence of muscular remnant of umbilical vessels. Segmental thinning of umbilical vein was observed only in study group, and thrombus was observed in the group of grade 2 asphyxia. **Conclusion:** The structural and histological factors that can affect the asphyxia neonatorum include amount of Wharton's jelly, mast cell counts distributed around the vessels, segmental thinning of umbilical vessels and thrombus.

Key words: Asphyxia, Neonates, Umbilical cord, Wharton's jelly, Histology.

INTRODUCTION

Birth asphyxia is defined as a failure to initiate, establish and sustain breathing at birth.^[1-4] Perinatal asphyxia is one of the most important causes of morbidity and mortality in neonates.^[4-6] Over 130 million infants born every year globally and about four million neonatal deaths occurred each year.^[2,6,7]

About one-quarter of all neonatal deaths are caused by perinatal asphyxia in worldwide.^[3,5] Prevalence of perinatal asphyxia varies from 1 to 6 per 1000 live births.^[8,9] Gebreheat *et al.* reported low birth weight, meconium-stained amniotic fluid, cesarean section, and prolonged maternal labour have been associated with perinatal asphyxia.^[5] Nayeri *et al.* reported emergent cesarean section, preterm labor (<37 weeks), birth weight lower than 2500g, need for resuscitation, nuchal cord, impaired biophysical profile, neonatal anemia and maternal infertility and its treatment are risk factors of asphyxia.^[10] Umbilical cord, which is mainly composed of umbilical vessels and elastic Wharton's jelly surrounding it, is a pathway of oxygen and nutrient supplies between mother and fetus. Therefore, its structural and histological abnormality can cause passage dysfunction. In this study, we conducted a research to explain several structural and histological features of umbilical cord that can have affection on asphyxia neonatorum in our country among umbilical factors.

MATERIALS AND METHODS

The study group included 85 cases (54 cases; grade 1, 31 cases; grade 2) which were diagnosed as asphyxia neonatorum between March 2019 and March 2021. Apgar scores were evaluated 2 times at 1 and 5 min just after birth and took the lowest scores to define asphyxia grade 2 for 1-4 points and asphyxia grade 1 for 5-7 points. 102 cases (normal) over 8 points were included in control group.

Procedure

To obtain umbilical cord specimens, we divided umbilical cord with their arteries and veins into 5 same parts and took 5mm of it from each division point. All specimens were fixed with 10% buffer formalin and embedded with paraffin and conduct thin segment as the thickness of 3mm. All segments were stained with Azan-Masson, toluidine blue, and hematoxylin-eosin. And we evaluated the percentage of Wharton's jelly, the average of mast cell counts and presence of muscular remnant, segmental thinning of umbilical vessels, thrombus.

The amount of Wharton's jelly was defined as the area percentage of Wharton's jelly to slice area of umbilical cord by using image-analyzing program-Motic Images Plus 2.0. Significance test was performed with *t*-test.

Ju Hyon-Saeng

Pyongyang University of Medical Science, Pyongyang, NORTH KOREA.

*Correspondence

Dr. Ju Hyon-Saeng

Pyongyang University of Medical Science, Pyongyang, NORTH KOREA.

Email: gagr5@ryongnamsan.edu.kp

History

- Submission Date: 27-06-2022;
- Review completed: 13-08-2022;
- Accepted Date: 27-08-2022.

DOI : 10.5530/ijcep.2022.9.3.28

Article Available online

<http://www.ijcep.org/>

Copyright

© 2022 Author(s). This is an open-access article distributed under the terms of the Creative Commons Attribution 4.0 International license.

Cite this article: Hyon-Saeng J. Study on Structural and Histological Indices of the Umbilicus in Neonatal Asphyxia. Int J Clin Exp Physiol. 2022;9(3):118-20.

RESULTS

As given in Table 1, the amount of Wharton's jelly of umbilical cord was significantly small in grade 2 asphyxia as $33.3 \pm 7.0\%$, compared with $50.3 \pm 4.1\%$ in control group. As given in Table 2, mast cell counts infiltrated around umbilical vessels in the group of grade 2 asphyxia were significantly small as $5.1 \pm 0.9/F$, compared with $16.7 \pm 4.8/F$ in control group. As given in Table 3, there was no significant difference in the presence of muscular remnant of umbilical vessels between study group and control group. As given in Table 4, segmental thinning of umbilical vessels was never observed in control group. On the other hand, there were 4 cases (7.4%) in grade 1 asphyxia and 8 cases (25.8%) in grade 2 asphyxia. Two cases with thrombus in umbilical vessels were observed in grade 2 asphyxia. Figure 1 shows the histology of the umbilicus.

DISCUSSION

Birth asphyxia is one of the worldwide problem of neonates.^[2] Perinatal asphyxia remains a significant cause of perinatal morbidity and mortality the world over.^[11] Wharton's jelly, the main component of umbilical cord with arteries and veins, plays the role of buffer to support blood circulation of umbilical arteries and veins. Therefore, abnormality of Wharton's jelly can have negative affection on maternal-fetal blood circulation. First of all, we estimated the amount of Wharton's jelly which is component of umbilical cord. According to our data, Wharton's jelly in grade 2 asphyxia was significantly small in study group as $33.3 \pm 7.0\%$, compared with $50.3 \pm 4.1\%$ in control group (Table 1). This may remind that lack of Wharton's jelly can be the cause of asphyxia neonatorum.

Table 1: Amount of Wharton's jelly of umbilical cord.

Component		Amount of Wharton's jelly
Study Group	Grade 1	50.1 ± 8.6
	Grade 2	$33.3 \pm 7.0^*$
Control group		50.3 ± 4.1

* $P < 0.05$ (compared with control group)

Table 2: Mast cell counts.

Component		Mast cell counts
Study group	Grade 1	12.2 ± 4.7
	Grade 2	$5.1 \pm 0.9^*$
Control group		16.7 ± 4.8

* $P < 0.05$ (compared with control group)

Table 3: Muscular remnant of umbilical vessels.

Component		Muscular remnant
Study group	Grade 1	1
	Grade 2	1
Control group		2

Table 4: Segmental thinning of umbilical vessels and thrombus.

Component		Segmental thinning	Formation of thrombus
Study group	Grade 1	4	-
	Grade 2	8	2
Control group		-	-

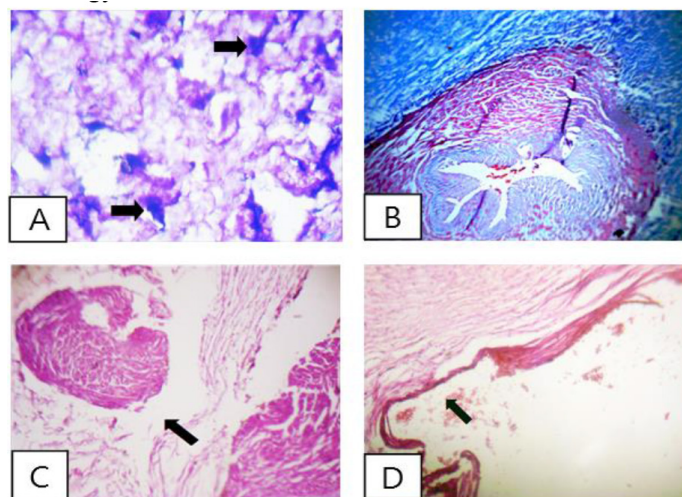


Figure 1: Histological indices of umbilical cord in healthy neonate and asphyxia neonate.

Infiltration of mast cells in normal neonatal umbilical cord (arrow). Toluidine blue $\times 400$.

Wharton's jelly (blue) and umbilical artery in normal neonatal umbilical cord (central). Azan-Masson $\times 200$.

C- Muscular remnant of umbilical vessels in grade 2 asphyxia (arrow). hematoxylin-eosin $\times 200$.

D- Segmental thinning of umbilical vessels in grade 2 asphyxia (arrow). hematoxylin-eosin $\times 200$.

Next, we estimated mast cell counts distributed around the umbilical vessels. In Wharton's jelly around the umbilical vessels, there appear mast cells after 3 months of pregnancy and they secrete heparin to prevent blood coagulation in long, curved umbilical cord. That is, we thought that this process is the basis of keeping pregnancy and one part of formation of umbilical cord and it might be related to pathway function of umbilical cord. According to the result of our research, in grade 2 asphyxia neonatorum, mast cell counts of umbilical cord were significantly small in study group as $5.1 \pm 0.9/F$ compared with $16.7 \pm 4.8/F$ in the control group (Table 2). Our data suggest that mast cell counts are related to asphyxia neonatorum.

Next, we evaluated the relationship between muscular remnant of vessels and asphyxia. In the previous references, we haven't found the data related to it. But existence of such remnant can cause the deficiency of maternal-fetal blood circulation. According to our data, there was no significant difference in the presence of muscular remnant of umbilical vessels between study and control group (Table 3). Finally, we observed the segmental thinning and presence of thrombus of umbilical vessels which are in direct charge of pathway function of umbilical cord. The segmental thinning of umbilical vein was never observed in control group. On the other hand, there were 4 cases (7.4%) in grade 1 asphyxia and 8 cases (25.8%) in grade 2 (Table 4).

We are not sure about the reason of the segmental thinning which is observed in asphyxia neonatorum, but it might be thought that it's caused by outside pressure or hypoxia by reduction of Wharton's jelly. And 2 cases with thrombus in umbilical vessels were observed in grade 2 asphyxia. It suggests relationship with mast cell counts distributed around the umbilical vessels. As a result, the structural and histological factors that can affect the asphyxia neonatorum include amount of Wharton's jelly, mast cell counts distributed around the vessels, segmental thinning of umbilical vessels and thrombus in our study.

CONFLICT OF INTEREST

The author declares no conflict of interest.

REFERENCES

1. Alaro D, Bashir A, Musoke R, Wanaiana L. Prevalence and outcomes of acute kidney injury in term neonates with perinatal asphyxia. *Afr Health Sci.* 2014;14(3):682-8. doi: 10.4314/ahs.v14i3.26, PMID 25352889.
2. Tasew H, Zemicheal M, Teklay G, Mariye T, Ayele E. Risk factors of birth asphyxia among newborns in public hospitals of Central Zone, Tigray, Ethiopia 2018. *BMC Res Notes.* 2018;11(1):496. doi: 10.1186/s13104-018-3611-3, PMID 30029614.
3. WHO. Guidelines on basic newborn resuscitation. World Health Organization; 2012.
4. Franks. Use of xenon with hypothermia for treating neonatal asphyxia. Patent Application Publication; 2007/0104796 A1.1-16.
5. Gebreheat G, Tsegay T, Kiros D, Teame H, Etsay N, Welu G, *et al.* Prevalence and associated factors of perinatal asphyxia among neonates in general hospitals of Tigray, Ethiopia, 2018. *BioMed Res Int.* 2018;2018:5351010. doi: 10.1155/2018/5351010, PMID 30515406.
6. Ugwu GI, Abedi HO, Ugwu EN. Incidence of birth asphyxia as seen in central hospital and GN children's clinic both in Warri Niger Delta of Nigeria: An eight year retrospective review. *Glob J Health Sci.* 2012;4(5):140-6. doi: 10.5539/gjhs.v4n5p140, PMID 22980387.
7. Shikuku DN, Milimo B, Ayebare E, Gisore P, Nalwadda G. Practice and outcomes of neonatal resuscitation for newborns with birth asphyxia at Kakamega County General Hospital, Kenya: A direct observation study. *BMC Pediatr.* 2018;18(1):167. doi: 10.1186/s12887-018-1127-6, PMID 29764391.
8. Vargas NSO. Prognostic Markers of Neonatal Outcomes in Full Term Neonates Suffering from Perinatal Asphyxia. *J Neonatal Biol;*04(3). doi: 10.4172/2167-0897.1000193.
9. Sehgal A, Wong F, Menahem S. Speckle tracking derived strain in infants with severe perinatal asphyxia: a comparative case control study. *Cardiovasc Ultrasound.* 2013;11(34):34. doi: 10.1186/1476-7120-11-34, PMID 24229323.
10. Nayeri F, Shariat M, Dalili H, Bani Adam L, Zareh Mehrjerdi F, Shakeri A. Perinatal risk factors for neonatal asphyxia in Vali-E-Asr Hospital, Tehran, Iran. *Iran J Reprod Med.* 2012;10(2):137-40. PMID 25242987.
11. Ghosh B, Mittal S, Kumar S, Dadhwal V. Prediction of perinatal asphyxia with nucleated red blood cells in cord blood of newborns. *Int J Gynaecol Obstet.* 2003;81(3):267-71. doi: 10.1016/s0020-7292(03)00124-3, PMID 12767568.

Cite this article: Hyon-Saeng J. Study on Structural and Histological Indices of the Umbilicus in Neonatal Asphyxia. *Int J Clin Exp Physiol.* 2022;9(3):118-20.