Int J Clin Exp Physiol. 2026;13(1):43-49.
https://www.ijcep.org

Case Report

Cotrimoxazole-Induced Toxic Epidermal Necrolysis in a Patient With Primary Sjögren Syndrome: A Case Report

Aditya Majumder[1,*], Jacob Mathews V[2], Indira Menon[3], Balakeshwa Ramaiah[1]

[1]Department of Pharmacy Practice, Karnataka College of Pharmacy, Bangalore, Karnataka, INDIA.
[2]Department of Rheumatology, Bangalore Baptist Hospital, Bangalore, Karnataka, INDIA
[3]Department of Critical Care, Bangalore Baptist Hospital, Bangalore, Karnataka, INDIA.

ABSTRACT

Toxic Epidermal Necrolysis (TEN) is a rare but potentially fatal severe cutaneous adverse reaction characterised by extensive epidermal necrosis and detachment, most commonly triggered by medications. We report a case of cotrimoxazole-induced TEN in an adult woman with primary Sjögren syndrome complicated by cutaneous vasculitis and previous basilar artery thrombosis in the setting of suspected central nervous system vasculitis. Four days after initiating cotrimoxazole, she developed fever, generalised burning sensation, mucocutaneous lesions, and rapidly progressive epidermal detachment involving approximately 60% of the body surface area. Causality was assessed using the Algorithm of Drug Causality for Epidermal Necrolysis (ALDEN), World Health Organisation-Uppsala Monitoring Centre (WHO-UMC) criteria, and the Naranjo Adverse Drug Reaction Probability Scale. Severity and preventability were additionally evaluated using the Hartwig-Siegel and Schumock-Thornton scales, respectively. The severity of illness was reflected by a SCORTEN score of 4 and a Grade 4 classification according to the Common Terminology Criteria for Adverse Events (CTCAE) version 5.0. Her hospital course was complicated by hypotension requiring vasopressor support and secondary multidrug-resistant bacterial and fungal infections. Following prompt withdrawal of cotrimoxazole, intensive supportive care, corticosteroid therapy, and targeted antimicrobial treatment, the patient demonstrated progressive clinical recovery and was discharged in stable condition. This case highlights the importance of early recognition and multidisciplinary management of TEN in patients with underlying autoimmune disease.

Keywords: Cotrimoxazole, Primary Sjögren syndrome, SCORTEN, Severe cutaneous adverse reaction, Skin lesions, Toxic epidermal necrolysis, Vasculitis.

Correspondence:
Dr. Aditya Majumder
Department of Pharmacy Practice,
Karnataka College of Pharmacy,
Bangalore, Karnataka, INDIA.
Email: adityamajumder55555@gmail.com

Received: 19-10-2026;
Revised: 03-11-2026;
Accepted: 03-11-2026.

www.ijcep.org

INTRODUCTION

TEN is a rare, severe, and potentially life-threatening mucocutaneous disorder characterised by epidermal detachment involving more than 30% of the body surface area. Along with Stevens-Johnson Syndrome (SJS), it is a potentially fatal adverse drug reaction that falls under the category of SCARs. With mortality rates ranging from 15% to 30%, the annual incidence of TEN is estimated to be between 0.4 and 1.2 cases per million population. Treatment timeliness, underlying comorbidities and the degree of skin involvement are the three main factors that affect these rates.[1-3]

DOI: 10.5530/ijcep.2026.13.1.6

Copyright Information :
Copyright Author (s) 2026 Distributed under Creative Commons CC-BY 4.0

Publishing Partner : Manuscript Technomedia. [www.mstechnomedia.com]

The pathophysiology of TEN is a complicated immune-mediated process that involves granzyme B and granulysin. Granulysin is a cytotoxic protein that is highly correlated with the severity of the disease and drug-specific cytotoxic CD8+ T cells and Natural Killer (NK) cells, which cause keratinocyte apoptosis. Recent data also suggest that inflammatory cascades and necroptosis are involved in the widespread destruction of the epidermis. Drugs, mostly sulphonamide antibiotics like cotrimoxazole, have been repeatedly identified as frequent triggers.[4,5]

Primary Sjögren Syndrome (pSS) is an autoimmune exocrinopathy characterised by lymphocytic infiltration of the lacrimal and salivary glands are more likely to experience immune dysregulation and drug hypersensitivity reactions, which can be exacerbated by previous or current immunosuppressive treatment. The presence of systemic vasculitis, such as cutaneous small vessel vasculitis and, subsequently, with basilar artery involvement in this patient, raises the possibility of multisystem complications.[6,7]

This case report describes cotrimoxazole-associated TEN in a patient with established pSS complicated by cutaneous vasculitis and previous basilar artery thrombosis with seizures. The case highlights the diagnostic and pharmacovigilance challenges of severe TEN in the setting of autoimmune disease and describes the clinical course, complications, multidisciplinary management, and outcome.

Case presentation

A 37-year-old female with a known history of pSS with cutaneous vasculitis, basilar artery thrombosis with seizures and hypothyroidism presented to the emergency department with acute-onset skin rashes. She was asymptomatic until four days prior to presentation, when she developed a burning sensation over her body after taking the tablet Co-trimoxazole (trimethoprim 160 mg and sulfamethoxazole 800 mg) twice daily for urinary tract infection. She had no previous exposure to cotrimoxazole and had no documented history of drug hypersensitivity. Lesions occurred over the face, mouth, bilateral lower limbs and genital area. She also reported fever of one day's duration. When she presented to the emergency room, cotrimoxazole was determined to be the suspected offending medication and was stopped right away. Her vitals on the first day of admission showed hypotension (70/40 mmHg), for which she was started on noradrenaline support. She was febrile with a temperature of 99.8°F, a respiratory rate of 22/min, a heart rate of 116/min and an oxygen saturation of 97% on room air. The chronological progression of clinical events, interventions, and outcomes is presented in Figure 1. The clinical diagnosis of TEN was based on extensive epidermal detachment exceeding 30% of estimated body surface area, widespread epidermal necrosis, and mucosal involvement in the appropriate temporal relationship to drug exposure. Histopathological confirmation was not obtained because of the patient's clinical instability. Alternative diagnoses were considered on the basis of the clinical presentation and available laboratory and microbiological investigations.

Causality, severity, and preventability of the suspected adverse drug reaction were assessed using complementary pharmacovigilance instruments. The Algorithm of Drug Causality for Epidermal Necrolysis (ALDEN) yielded a score of 6, supporting cotrimoxazole as a very probable culprit drug. The World Health Organisation-Uppsala Monitoring Centre (WHO-UMC) system classified the relationship as probable/likely, while the Naranjo Adverse Drug Reaction Probability Scale yielded a score of 8, corresponding to a probable association. Severity was assessed using the Hartwig-Siegel scale and was classified as Level 5, indicating a severe adverse drug reaction requiring intensive medical care. Preventability was assessed using the modified Schumock-Thornton criteria and was classified as not preventable, as no documented previous reaction, inappropriate indication or dosing, relevant drug interaction, omitted required monitoring, poor compliance, or other identifiable preventive measure was identified. Disease severity was additionally assessed using SCORTEN and the Common Terminology Criteria for Adverse Events (CTCAE) version 5.0. The SCORTEN score was 4, and the reaction was classified as Grade 4 according to CTCAE version 5.0.

www.ijcep.org

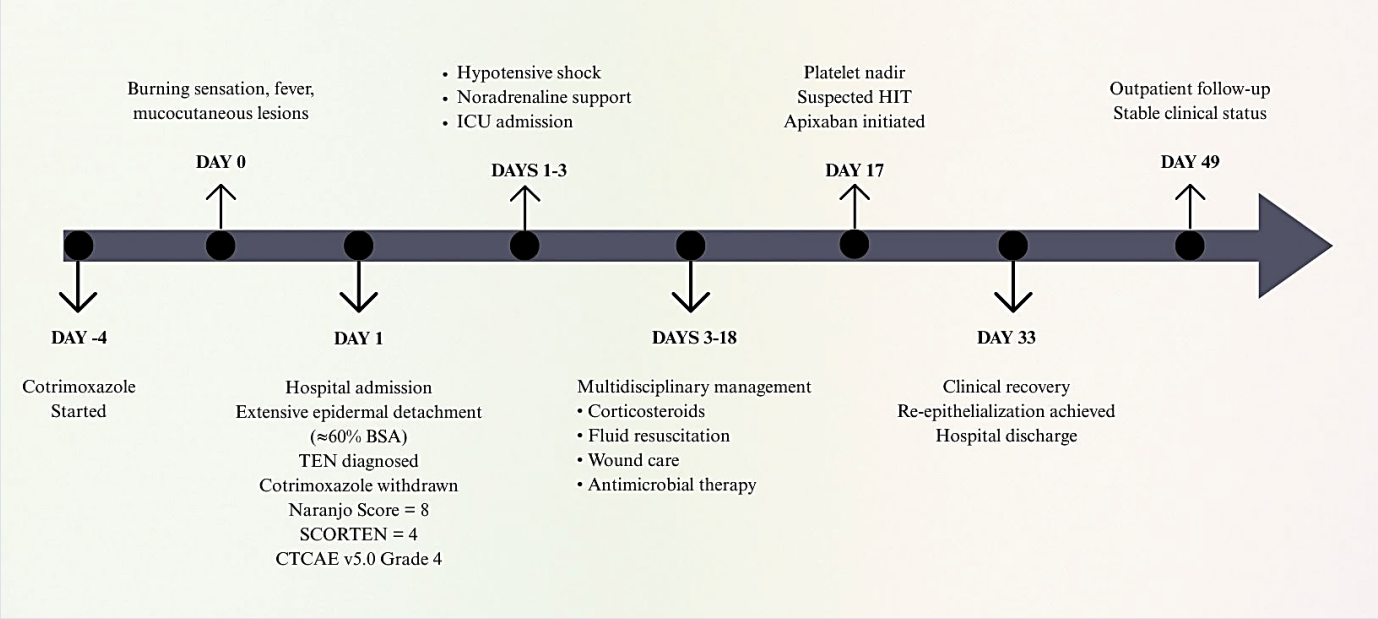

Figure 1: Clinical timeline illustrating the onset, progression, multidisciplinary management, and recovery of cotrimoxazole-induced Toxic Epidermal Necrolysis (TEN).

Table 1: Serial Haematological Parameters of the Patient.

	Haemoglobi (g/dL)	Haematocrit (%)	Total RBC Count (x 106/mm³	Total WBC count (x 103/mm³	Neutrophils (%)	Lymphocyte (%)	Monocytes (%)	Eosinophils (%)	Basophils (%)	MCV (FL)	MCH (PG)	MCHC (g/dL)	RDW (%)	Platelet Count (x 103/mm3)
Day 01	11.7	35.4	3.4	4.4	70	19	10	0	3	94	31.2	32.9	17.1	104
Day 03	10.3	31.7	3.34	3.4	76	18	6	0	0	94.9	30.7	32.3	17.4	74
Day 05	11.4	34.8	3.69	3.2	72	18	10	0	0	94.2	30.8	32.7	17.3	87
Day 09	10.5	31.5	3.31	5.5	70	20	10	0	0	94.9	31.7	33.3	17.3	104
Day 12	10.3	31.1	3.24	17.3	93	3	4	0	0	96	31.6	32.9	18.6	120
Day 14	-	-	-	4.5	77	13	0	10	0	-	-	-	-	-
Day 16	8.5	26.2	2.68	5.8	85	8	6	0	1	97.7	31.6	32.4	20.8	75
Day 17	8	24.8	2.55	4.3	63	26	10	0	1	97.3	31.2	32.1	20.1	37
Day 18	8.5	25.7	2.66	4.1	68	20	10	0	2	96.8	32.2	33.2	20.8	40
Day 21	8.6	26.5	2.72	4.3	70	20	9	0	1	97.5	31.5	32.3	20.3	62
Day 25	9.9	30.5	3.09	4.8	60	29	10	0	1	98.7	32.1	32.5	4.3	102
Day 28	9.5	28.7	2.94	5.1	72	19	9	0	0	97.5	32.3	33.1	19.9	150
Day33	8.9	27.7	2.81	4.5	59	29	10	1	1	98.6	31.7	32.1	19.2	133
Day 49	10.2	31	3.18	3.7	63	-	-	-	-	-	-	-	-	-

Initial laboratory workup revealed electrolyte disturbances, hypoalbuminemia and elevated liver enzymes. Serial haematological changes during hospitalisation are summarised in Table 1. Blood and urine cultures grew multidrug-resistant Klebsiella, *Candida tropicalis*, and *Candida krusei* during different stages of her hospital stay. Central line tip culture confirmed candidemia. Imaging with chest X-ray did not show any abnormalities. Autoimmune serology demonstrated a positive ANA (3+ speckled pattern), anti-Ro/SSA positivity (176.3 RU/mL), anti-La/SSB positivity, and Ro-52 positivity. The complete autoimmune and thrombophilia workup is summarised in Table 2. Anti-dsDNA antibodies were negative, while complement levels (C3 and C4) were within normal limits. Testing for MPO-ANCA, PR3-ANCA, anticardiolipin antibodies, anti-β2 glycoprotein-I antibodies, lupus anticoagulant, and cryoglobulins was negative, supporting a diagnosis of primary Sjögren syndrome with systemic vasculitic manifestations rather than systemic lupus erythematosus or antiphospholipid syndrome.

Treatment

On admission, intravenous fluids and inotropic support were used to stabilise the patient's haemodynamics. Based on culture and sensitivity results, empirical broad-spectrum antibiotics (piperacillin+tazobactam) and fluconazole were started and subsequently escalated to meropenem, teicoplanin and tigecycline during the course of her ICU stay. In addition to careful skin care with banana leaf dressings, hydrocortisone therapy was initiated as she was already on low-dose steroids for cutaneous vasculitis and clinically suspected Central Nervous system (basilar artery) vasculitis. Later, Voriconazole replaced fluconazole as the treatment of choice for fungal infections. Heparin was started as a preventive measure against deep vein thrombosis and stopped due to suspected Heparin-Induced Thrombocytopenia (HIT) and replaced with apixaban. Albumin infusions, electrolyte correction, and nutritional supplements were given as part of the supportive care.

Table 2: **Autoimmune and Thrombophilia Workup.**

Investigation	Result
ANA	Positive (3+ Speckled)
Anti-Ro/SSA	Positive
Anti-La/SSB	Positive
Ro52	Positive
Anti-dsDNA	Negative
C3	Normal
C4	Normal
MPO-ANCA	Negative
PR3-ANCA	Negative
Anticardiolipin Ab	Negative
β2-GPI Ab	Negative
Lupus anticoagulant	Negative
Cryoglobulins	Negative

***DAY-1 refers to the first day of admission, DAY-33 refers to the day of discharge, and DAY-49 refers to the first day of follow-up after discharge.

Follow-up and outcomes

The patient's condition gradually improved over the course of the next four weeks in the hospital. Fever decreased and skin lesions healed with scab shedding. The antifungal medication was switched to an oral formulation after the Central Venous Catheter (CVC) was removed. Subsequently, venous Doppler revealed bilateral deep vein thrombosis of both legs, and she was initiated on a therapeutic dose of Apixaban. She was discharged on low-dose steroids, anticoagulants and a clear plan for ongoing rehabilitation at home. Representative images demonstrating the extent and distribution of epidermal detachment during TEN are shown in Figure 2.

DISCUSSION

As a rare and potentially fatal mucocutaneous adverse drug reaction, TEN causes extensive epidermal necrosis that impacts



Figure 2: Clinical manifestations of toxic epidermal necrolysis involving (A) face, (B) lower limbs, (C) right upper limb, (D) posterior trunk.

www.ijcep.org

over 30% of the total body surface area. One of the most frequently reported medications that cause TEN and SJS is the commonly used sulfonamide antibiotic cotrimoxazole (trimethoprim-sulfamethoxazole). Cotrimoxazole-induced TEN has been reported in several case reports, including those involving patients who did not have autoimmune diseases, which make them more vulnerable to drug hypersensitivity reactions. For instance, a 66-year-old man with cotrimoxazole-induced TEN that involved 60-70% BSA was successfully treated with corticosteroids and broad-spectrum antibiotics, according to a case report by Gaire *et al.*[8] BSA estimation differed between the two methods, with Wallace's Rule of Nines estimating >80% involvement and the Lund-Browder chart estimating approximately 60%. The discrepancy was documented because both methods were used during clinical assessment. Previously reported cases and the present case are compared in Table 3.

The high risk of severe cutaneous reactions associated with trimethoprim-sulfamethoxazole was also highlighted by Bhosale *et al.*, who reported TEN in a young female.[9] According to Alajaji *et al.*, their cohort gradually improved as a result of early diagnosis, discontinuation of cotrimoxazole and appropriate multidisciplinary supportive care, which included immunosuppressants and infection control.[3]

Autoimmunity and TEN

Patients with autoimmune diseases (like pSS) may be more susceptible to exaggerated drug reactions because of immune dysregulation. The coexistence of Primary Sjogren's syndrome with vasculitis, as in the case presented, is less common and complicates the clinical course. Crucially, post-TEN complications such as secondary autoimmune disorders have been documented, suggesting a complex interaction between

Table 3: Comparison of cotrimoxazole-associated TEN cases with the present case.

Study	Age/ Gender	Underlying diseases	Drug exposure	BSA	Treatment	Outcome
Gaire *et al.* (2024) [8]	66-year/male	Diabetes mellitus, hypertension, nephrotic syndrome	8 days	60-70%	Imipenem and Cilastatin, azithromycin, dexamethasone, hydrocortisone, Filgrastim.	Recovered
Bhosale *et al.* (2013) [9]	26-year/female	Not mentioned	Not mentioned	60%	Offending drugs withdrawn, intravenous fluids, hydrocortisone, antibiotics, wound care, and topical antiseptic treatment.	Recovered
Veiga *et al.* (2025) [10]	53-year/male	No significant previous medical history	17 days	>30%	Offending drugs withdrawn, supportive treatment with volume resuscitation, nutritional support and wound dressing, cyclosporine and topical corticosteroids for ocular lesions.	Discharged without cutaneous sequelae; ocular erosions persisted and continued to require treatment
Present case	37-year/female	Primary Sjögren's syndrome with cutaneous vasculitis, basilar artery thrombosis with seizures, and hypothyroidism.	4days	>30%	Offending drugs withdrawn; piperacillin-tazobactam and fluconazole were administered, later escalated to meropenem and tigecycline. Fluconazole was subsequently replaced by voriconazole. Supportive management included careful skin care, banana-leaf dressing, hydrocortisone, electrolyte correction, albumin infusion, nutritional supplementation, and blood-thinning agents.	Recovered

www.ijcep.org

host susceptibility and immune system disruption brought on by TEN.[10,11]

A retrospective cohort study by Almutairi *et al.* reported an association between anti-SS-A antibody positivity and greater clinical severity among patients with SJS/TEN. In that study, anti-SS-A-positive patients demonstrated greater severity and mucosal/visceral involvement. Our patient was also positive for anti-SSA, making this finding clinically noteworthy.[12,13] However, the observational nature of the available evidence does not establish anti-SSA positivity as an independent causal risk factor for TEN.[14]

The literature documents long-term sequelae of TEN in which patients with no prior history of autoimmunity developed full-blown Sjögren's syndrome and concomitant Hashimoto's thyroiditis within 2 to 5 years of surviving a TEN event, purely due to this post-necrolysis immune restructuring. The proposed mechanism is that during the acute phase of TEN, a patient's Regulatory T-cells (Tregs) undergo massive functional impairment. During the subsequent immune recovery stage, this lingering Treg dysfunction can cause a permanent loss of self-tolerance.[15]

Hepatic abnormalities during the clinical course in TEN

Our patient displayed liver transaminitis which peaked by the end of the second week. The derangement in liver function tests is also well documented in the literature. The trend of liver function parameters during hospitalisation is shown in Table 4. Studies indicate that the incidence of liver injury or Drug-Induced Liver Injury (DILI) in SJS/TEN patients ranges from roughly 9.6% to 13.4%, which is also associated with poor prognosis and increased mortality. The timing and nature of the peak LFT derangement in SJS/TEN depend on the specific pattern of liver injury:

Hepatocellular Pattern (Early Peak)

For about 35% of patients, transaminases (ALT and AST) peak rapidly within the first 3 to 5 days, coinciding with acute fever and initial bullous skin eruptions.

Cholestatic/Mixed Pattern (Delayed Peak)

For others, total bilirubin and Alkaline Phosphatase (ALP) peak later, typically 1 to 2 weeks into admission, driven by progressive bile duct inflammation, drug clearance, stress, or secondary sepsis.[13]

Blood counts in TEN

The drop in blood counts and platelets observed in our patient in the first week of the illness is well described in patients with TEN. A landmark multi-centre review of TEN clinical findings published in the *Archives of Dermatology* demonstrated that thrombocytopenia, neutropenia, and lymphopenia are statistically linked to a significantly worsened prognosis and higher mortality rates in TEN patients.[12]

Similar to many published case reports, such as those by Bhosale *et al.* and Gaire *et al.*, histopathological evidence was limited because the patient's instability precluded a biopsy. Although the single-patient nature of this case limits its generalisability, it provides unique information on TEN's overlap with underlying autoimmune disease to support additional research in such cohorts.[8,9]

This highlights the need for early diagnosis and heightened clinical vigilance, as concurrent steroid therapy in patients with autoimmune diseases may mask symptoms and delay the presentation of TEN. This case report emphasises how crucial customised treatment regimens are when TEN coexists with systemic autoimmune diseases.[4] Early diagnosis and better results can be achieved by recognising the severity of TEN, especially in patients with autoimmune disorders who are also

Table 4: Serial Liver Function Tests (LFT) during hospitalisation.

	Day 01	Day 08	Day 10	Day 12	Day 16	Day 19	Day 21	Day 24	Day 33
Total protein Serum (g/dL)	4.27	4.05	3.86	4.25	4.22	4.76	4.77	5.43	6.32
Albumin Serum (g/dL)	2.1	1.9	1.7	1.9	2.3	205	2.6	3	3.1
Bilirubin Direct (mg/dL)	0.6	0.1	0.1	0.3	0.6	0.3	0.2	0.2	0.2
Bilirubin Total (mg/dL)	1.6	0.8	0.8	0.9	1.3	1.0	1.0	1.1	1.1
Alkaline Phosphatase serum (U/L)	169	378	302	290	215	168	142	170	272
AST (U/L)	58	139	152	162	175	55	65	52	54
ALT (U/L)	36	108	112	108	70	42	39	35	42
Gamma Glutamyl Transferase (U/L)	260	1114	899	899	504	356	340	303	253

www.ijcep.org

on immunosuppressants. Additionally, recording these intricate cases helps to raise clinical awareness and offers insightful information for upcoming studies on adverse drug reactions in susceptible groups.

CONCLUSION

The uncommon and potentially SCAR known as TEN necessitates immediate intervention and a high level of concern. This report demonstrates the intricate relationship between TEN and an underlying pSS complicated by vasculitis, particularly in the context of concurrent low-dose steroid use. This rare multisystemic presentation b caused by cotrimoxazole-induced TEN in the setting of preexisting pSS has not been reported in the literature. Clinicians need to be aware that even well-known and frequently prescribed medications (like cotrimoxazole), can cause uncommon serious side effects like TEN. In such cases, early diagnosis is essential to reduce mortality rate and progression of the disease conditions. Improving outcomes in such vulnerable populations requires early detection, timely removal of the offending agent and coordinated multidisciplinary care. The significance of careful drug history evaluation and monitoring is emphasised by this case, particularly for patients who have comorbidities or underlying immune dysregulation that make them more vulnerable to drug hypersensitivity. In order to improve patient safety, advance clinical knowledge and inform risk management plans, it is essential that such unusual and complex cases be reported. This case reinforces the need to educate healthcare providers about the unpredictability of adverse drug reactions, including those caused by common medications. In the end, being alert for uncommon but potentially fatal drug-induced events can help with early intervention, lower morbidity and save lives.

Patient perspective: The hospitalisation was terrifying, especially losing skin like that. I feel lucky to have survived.

ABBREVIATIONS

ADR: Adverse Drug Reaction; **ANA:** Antinuclear Antibody; **CVC:** Central Venous Catheter; **pSS:** Primary Sjögren's Syndrome; **SCARs:** Severe Cutaneous Adverse Reactions; **SJS:** Stevens-Johnson Syndrome; **TEN:** Toxic Epidermal Necrolysis.

CONFLICT OF INTEREST

The authors declare that there is no conflict of interest.

REFERENCES

1. Wasuwanich P, So JM, Chakrala TS, Chen J, Motaparthi K. Epidemiology of Stevens-Johnson syndrome and toxic epidermal necrolysis in the United States and factors predictive of outcome. JAAD Int. 2023;13:17-25. doi: 10.1016/j.jdin.2023.06.014. PMID: 37575514.
2. Chaby G, Maldini C, Haddad C, Lebrun-Vignes B, Hemery F, Ingen-Housz-Oro S, *et al.* Incidence of and mortality from epidermal necrolysis (Stevens-Johnson syndrome/toxic epidermal necrolysis) in France during 2003-16: a four-source capture-recapture estimate. Br J Dermatol. 2020;182(3):618-24. doi: 10.1111/bjd.18424. PMID: 31396952.
3. Alajaji A, Shekaran JC, Aldhabbah OM, Alhindi HA, Almazyad NS, Aljutayli ZA, *et al.* Toxic Epidermal Necrolysis (TEN)/Stevens-Johnson Syndrome (SJS) Epidemiology and Mortality Rate at King Fahad Specialist Hospital (KFSH) in Qassim Region of Saudi Arabia: A Retrospective Study. Dermatol Res Pract. 2020;2020:1-3. doi: 10.1155/2020/7524726. PMID: 33133181.
4. Downey A, Jackson C, Harun N, Cooper A. Toxic epidermal necrolysis: Review of pathogenesis and management. J Am Acad Dermatol. 2012;66(6):995-1003. doi: 10.1016/j.jaad.2011.09.029. PMID: 22169256.
5. Hama N, Aoki S, Chen C, Hasegawa A, Ogawa Y, Vocanson M, *et al.* Recent progress in Stevens-Johnson syndrome/toxic epidermal necrolysis: Diagnostic criteria, pathogenesis and treatment. Br J Dermatol. 2024;192(1):9-18. doi: 10.1093/bjd/ljae321. PMID: 39141587.
6. Higashida-Konishi M, Izumi K, Shimada T, Hama S, Oshige T, Oshima H, *et al.* Allergic disorders and their risk factors in primary Sjögren's syndrome. World Allergy Organ J. 2023;16(2):100745. doi: 10.1016/j.waojou.2023.100745. PMID: 36788991.
7. Antonen JA. Adverse Drug Reactions in Sjögren's Syndrome: Frequent allergic reactions and a specific trimethoprim-associated systemic reaction. Scand J Rheumatol. 1999;28(3):157-9. doi: 10.1080/03009749950154220. PMID: 10380837.
8. Gaire S, Chhetri ST. Co-Trimoxazole-Induced Toxic Epidermal Necrolysis: A Case Report From Nepal. Clin Case Rep. 2024;12(12):e9679. doi: 10.1002/ccr3.9679. PMID: 39619308.
9. Bhosale RR, Bodke PS, Patil AV, Bhurke SH. Trimethoprim-sulfamethoxazole-induced toxic epidermal necrolysis: a case report. Int J Basic Clin Pharmacol. 2013;2(6):841-2. doi: 10.5455/2319-2003.ijbcp20131236.
10. Veiga, C., Sevivas, R., Paulo, G., Coelho, I., & Lemos Costa, C. (2025). Cotrimoxazole-Induced Toxic Epidermal Necrolysis: A Clinical Case. *SPMI Case Reports*, *3*(2), 51-4. https://doi.org/10.60591/crspmi.330
11. Youvalakshmi S, Logamoorthy R, Karthikeyan K. Drug reaction with eosinophilia and systemic symptoms with toxic epidermal necrolysis-like rash in systemic sclerosis and overlapping Sjögren's syndrome: A double trouble triggered by a herbal medicine. Indian J Dermatol Venereol Leprol. 2024;0:1-3. doi: 10.25259/IJDVL_726_2024. PMID: 39912181.
12. Revuz J. Toxic Epidermal Necrolysis. Archives of Dermatology. 1987;123(9):1160-5. doi: 10.1001/archderm.1987.01660330071012.
13. Liu O, Zhang Z, Li S, Zhang Z, Yu K, Duan X, *et al.* Clinical features, risk factors, and prognostic markers of drug-induced liver injury in patients with Stevens-Johnson syndrome/toxic epidermal necrolysis. Indian J Dermatol. 2020;65(4):274-8. doi: 10.4103/ijd.ijd_217_19. PMID: 32831367.
14. Watanabe R, Watanabe T, Yamaguchi Y. Anti-SS-A antibody is a potential predictor of severe Stevens-Johnson syndrome and toxic epidermal necrolysis: a retrospective cohort study. J Am Acad Dermatol. 2024;90(2):385-7. doi: 10.1016/j.jaad.2023.09.061. PMID: 37778660.
15. Couissi I, *et al.* Autoimmune Diseases as a Late Complication of Toxic Epidermal Necrolysis: A Case Report. J Dermatol Res. 2023;4(2):1-4. https://doi.org/10.46889/JDR.2023. 4207.

Cite this article: Majumder A, V JM, Menon I, Ramaiah B. Cotrimoxazole-Induced Toxic Epidermal Necrolysis in a Patient With Primary Sjögren Syndrome: A Case Report. Int J Clin Exp Physiol. 2026;13(1):43-49.

www.ijcep.org